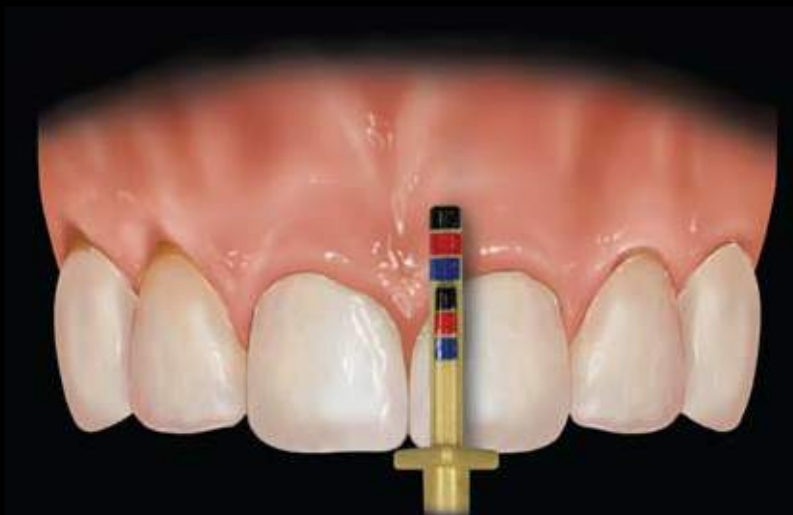


# A BIOMETRIC APPROACH TO AESTHETIC CROWN LENGTHENING: PART II—INTERDENTAL CONSIDERATIONS

Stephen J. Chu, DMD, MSD, CDT\* • Mark N. Hochman, DDS† • Paul Fletcher, DDS‡



*Optimizing the aesthetic outcome for patients requiring periodontal aesthetic restorative treatment has become a primary objective in contemporary dentistry. Techniques that simplify and enhance quality of treatment provide substantial benefits to patients and clinicians. This article describes new concepts associated with interdental changes due to alterations in tooth and contact area position, and addresses the need for treatment of the interdental papillae. An innovative approach to aesthetic interdental periodontal crown lengthening will be discussed.*

## Learning Objectives:

This article describes the use of innovative protocols to ensure maintenance of interdental aesthetics following alterations in tooth and contact area positions. Upon completing this article, the reader should:

- Understand the role of interdental periodontal crown lengthening on the maintenance of natural-looking interproximal tissues.
- Be aware of the aesthetic requirements for optimal interdental papillae.

*Key Words: crown lengthening, interdental, periodontal, aesthetic*

\*Clinical Associate Professor and Director, Advanced CDE Program in Aesthetic Dentistry, Department of Periodontology and Implant Dentistry, New York University College of Dentistry, New York, New York; private practice, New York, New York.

†Clinical Assistant Professor, Departments of Periodontology and Implant Dentistry and Post-graduate Orthodontics, New York University College of Dentistry, New York, New York; private practice, New York, New York.

‡Clinical Professor, Department of Periodontology and Implant Dentistry, New York University College of Dentistry, New York, New York; private practice, New York, New York.

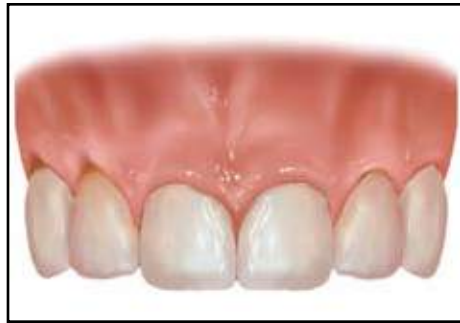Stephen J. Chu, DMD, MSD, CDT, 150 East 58th Street, Ste 3200, New York, NY 10155  
Tel: 212-752-7937 • E-mail: SChuDMD@aol.com

Surgical crown lengthening in periodontally healthy patients has traditionally been performed to re-establish the biologic width of the dentogingival complex (DGC) as an adjunct to aesthetic restorative procedures.<sup>1</sup> Considerable variation in the magnitude or length of this complex was reported; however, the mean sulcus depth was 0.69 mm, epithelial attachment was 0.97 mm, and the connective tissue was 1.07 mm. Therefore, the total length of the DGC was 2.73 mm in depth mid-facially. Interdentally, a greater number of 4 mm to 4.5 mm has been reported by Kois and Tarnow, who theorized that the increased DGC may be due to hypertrophy of the interdental (ID) tissue stimulated by the apical extent of the contact area.<sup>2,3</sup> Based on these dimensions, several authors suggested that a minimum of 3 mm of supra-crestal tooth structure be obtained during surgical crown lengthening.<sup>4</sup> Other authors have suggested that supra-crestal tooth structure ranges from 3.5 mm to 5.25 mm, depending on the placement of the restorative margin as well as location of the tissue (ie, mid-facial [MF] versus ID).<sup>5</sup> Therefore, it is important to establish a consistent measurement representative of the DGC dimension, both mid-facially and interdentally, which is critical for health as well as aesthetic and restorative success when performing surgical crown lengthening.

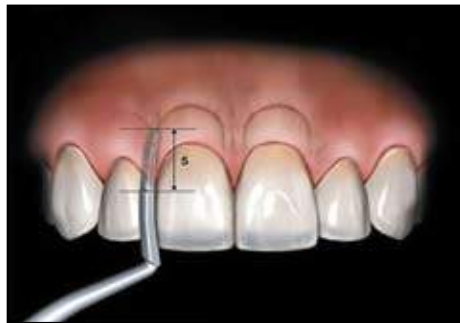The apical point of the contact area in relation to the crest of bone defines the height of the ID papillae.<sup>6</sup> To date, no technique describes clearly or definitively the treatment of the ID papillae during surgical crown lengthening, particularly when the apical point of the ID contact area has super-erupted coronally secondary to incisal attrition (Figure 1). The relocation of the apical point of the contact area is frequently required in such cases and, hence, the repositioning of the papillae and associated osseous crest in an apical direction is a requirement in treatment.

### Background

Traditionally, dental instruments (eg, periodontal probes) have been used as a clinical indicator to detect diseases such as periodontitis using numerical values and/or bleeding upon probing as indications of health or stages of disease.<sup>7</sup> Recently, instrumentation has been created to address these needs, specifically, aesthetic tooth and gingival architecture discrepancies from diagnosis to treatment (ie, Chu's Aesthetic Gauges, Hu-Friedy, Inc, Chicago, IL).<sup>7,8</sup> Aesthetic and anatomic tooth dimensions can now be evaluated and treated by an objective numerical analysis. These innovative aesthetic gauges have been developed to eliminate the subjective approximations offered by direct visual assessment of aesthetic tooth proportions. Once proper tooth



**Figure 1. Commonly, the apical point of the proximal contact area requires repositioning during crown lengthening procedures.**



**Figure 2. Assessment of the interproximal osseous crest using the sounding gauge.**

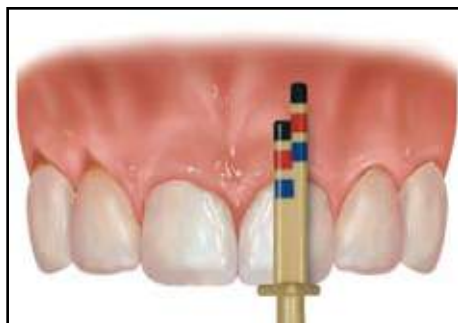
size and proportion are established, the appropriate adjunctive periodontal procedure can be determined (ie, MF and ID clinical crown lengthening).<sup>8,9</sup>

### Innovative Instrumentation

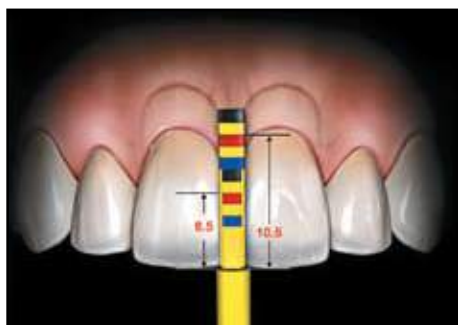
Aesthetic crown lengthening is a multi-faceted decision-making process with the endpoint being whether hard and soft tissues can be excised and if they should be repositioned.<sup>5</sup> Excessively short teeth with a lack of tooth display concurrent with excessive gingival display invariably entail clinical crown lengthening. The proportion gauge is efficiently used to diagnose the length discrepancy and, more importantly, quantify the amount of discrepancy in a color-coded visual design.

### Proportion Gauge

The *Proportion Gauge* (PG) represents an objective mathematical appraisal of tooth size ranges in a visual format for clinical and laboratory use. Through the employment of such instrumentation, the clinician is able to apply aesthetic values to a patient chairside (directly) or in the laboratory (indirectly) for projected treatment planning



**Figure 3.** The shorter arm of the BLPG tip projects the clinical crown height and the longer arm projects where the bone crest should be.



**Figure 4.** The papilla tool is used to access the proper position of the papilla measured from the incisal edge position.

and to objectively forecast the intended treatment outcome. The incisal edge position must be established prior to diagnostic and procedure-based measurements. In addition, correct incisal edge position and tooth size must be determined prior to performing any irreversible surgical aesthetic periodontal procedure, whether it is clinical crown lengthening or soft tissue root coverage.

### **Sounding Gauge**

The sounding and crown lengthening gauges are designed for the periodontal surgeon to diagnose biologic width dimension and simultaneously correct the proper clinical crown length. Present armamentarium for such diagnoses consist of periodontal probes and calipers or surgical templates fabricated from indirect, polymer-based waxups. These aesthetic gauges are designed to replace present techniques/systems; therefore, they are visual in nature, allowing simple, efficient, and predictable diagnosis of tooth width and/or length complications as well as gingival length discrepancies.

The sounding gauge is used in aesthetic crown lengthening procedures to determine the bone level prior to flap reflection. This gauge helps provide a quick and simple

analysis of the osseous crest location both mid-facially and interdentally. Fabricated from surgical-grade stainless steel, this device is honed to precisely pierce the supracrestal gingival fibers with reduced trauma. Laser markings define the average sulcus depth (1 mm), MF DGC (3 mm), and ID DGC (5 mm). The aesthetic sounding gauge is designed to make MF and ID osseous crest location easier, faster, and more predictable (Figure 2; for additional illustrations depicting the armamentarium used in this example, please visit this article online at [www.ppad.com](http://www.ppad.com)).

### **Crown Lengthening Gauge**

The *crown lengthening gauge*, a double-ended instrument, has the Biologic PerioGauge (BLPG) tip on one end, and the papilla tip on the opposite end. The BLPG tip is used to achieve the proper MF clinical crown and biologic crown (osseous crest to incisal edge position) lengths during surgical crown lengthening procedures (Figure 3).<sup>9</sup> The papilla tip follows the use of the BLPG tip to establish the correct aesthetic position of the ID papilla from the incisal edge, quantified to the corrected MF clinical crown length, before the flap is approximated and sutured.

The papilla tip has a longer arm positioned behind the overlaid shorter arm. The long arm is color-coded to determine the ID biologic crown length, and the shorter arm helps determine the ID clinical papilla position corresponding to the teeth being measured. The papilla tip is used in conjunction with the BLPG tip during the aesthetic crown lengthening procedure to determine the ideal position of the interdental papilla, relative to the corrected MF tooth length, when the flap is approximated to the final position and sutured.

Considering the facts of clinical perception research, the ideal aesthetic position of the ID papilla should be between 50% and 70% of the overall length of the clinical crown when measured from the incisal edge position.<sup>6,10</sup> The ID biologic crown (interproximal bone crest to the incisal edge) is 3 mm to 5 mm greater (4-mm average) than the clinical ID papilla position.<sup>3</sup> Hence, the tip is color-coded with preset interproximal dentogingival complex measurements of 4 mm.

For example, the measurement on the outer margin of the red band of the inner arm is 6.5 mm. This measurement is 60% of the corrected maxillary central incisor average clinical crown length of 11 mm, which is based on an average width of 8.5 mm ( $0.60 \times 11 \text{ mm} = 6.5 \text{ mm}$ ). The outer margin of the red band on the long arm is 10.5 mm, which is 6.5 mm plus 4 mm needed to provide adequate ID DGC (Figure 4). Both of these ID structures must be visualized and identified simultaneously, identical to what is required mid-facially. When the interproximal biologic crown is determined with a particular color band on

the longer outer arm, the ID papilla is positioned at the corresponding color band on the shorter inner arm.

### Clinical Applications

Tooth size is such a critical facet in aesthetics and has clinical relevance in every area of the dental arena including restorative dentistry, orthodontics, periodontics, and implant dentistry. These gauges allow standardization of tooth size and gingival architecture parameters as well as objective communication between clinicians involved in comprehensive patient care from diagnosis to the final aesthetic restorative outcome. More specifically, when short teeth are present, requiring aesthetic crown lengthening, precision instrumentation can be used to replace existing and less accurate means of measurement.

Aesthetic periodontal therapy invariably demands addition and/or subtraction procedures in an effort to restore the proper tooth size and form. These gauges facilitate easy and quick diagnosis for addition (grafting) or subtraction (crown lengthening) procedures to correct the tooth size discrepancies.

### Case Presentation

A 64-year-old female patient was displeased with the size, shape, and color of her maxillary anterior teeth and gingiva (Figure 5). Following a comprehensive periodontal, restorative, and radiographic evaluation, it was determined that periodontal aesthetic crown lengthening surgery was required to address the patient's chief complaints. It is critical to note that not only the MF tissues migrated incisally, but also the apical point of the proximal contact area, interdentally (Figure 6).

Studies have shown that periodontists tend to underestimate the amount of hard and soft tissues that must be removed during crown lengthening surgery.<sup>11</sup> It was, therefore, decided to utilize the crown lengthening gauge as an objective visual guide in establishing the correct occlusogingival clinical dimensions of the teeth relative to the mesiodistal aspect, as well as the final biologic crown length and correct papilla position.

The correct incisal edge position of the teeth was first established, reflective of the final restoration. In some cases, this step may even involve the temporization of the teeth if necessary, with either composite and/or acrylic resin materials. Once the incisal edge position was established, the incisal stop of the T-Bar PG was placed on the incisal edge of the tooth being treated. The final length of the clinical crown has been shown to be a function of the final width of the clinical crown, and the colored markings on the horizontal bar of the PG corresponded to the colored markings on the vertical

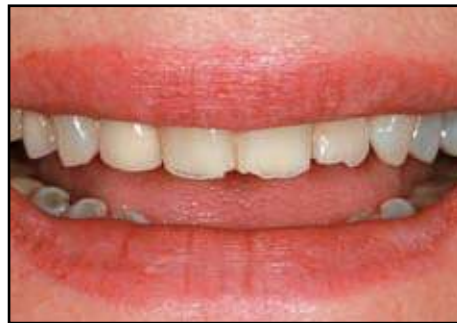

Figure 5. Preoperative appearance of the patient's smile. The existing IEP was deemed appropriate.

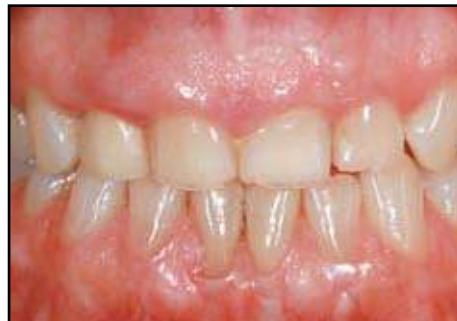

Figure 6. Intraoral view of the disproportionate maxillary anterior dentition in occlusion.

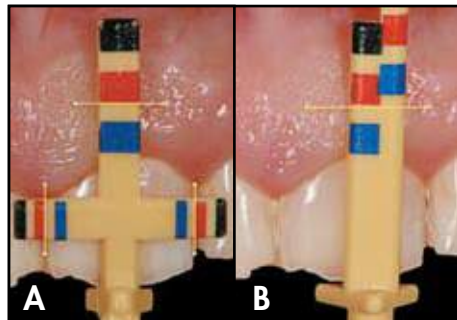


Figure 7A. The tooth proportion gauge was used to assess clinical crown length. 7B. The BLPG tip was used to expose the MF tooth structure.

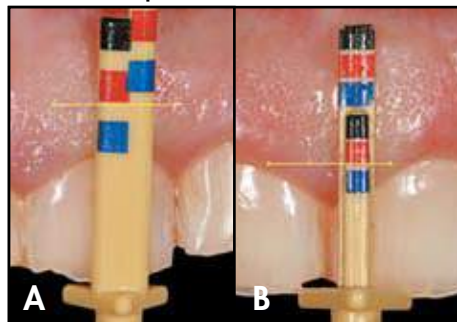
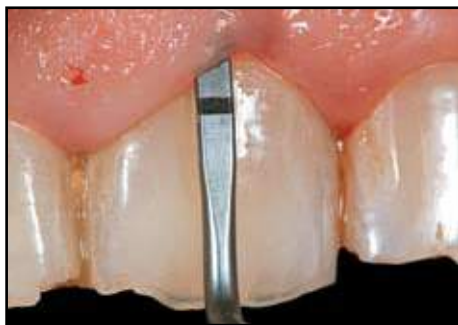
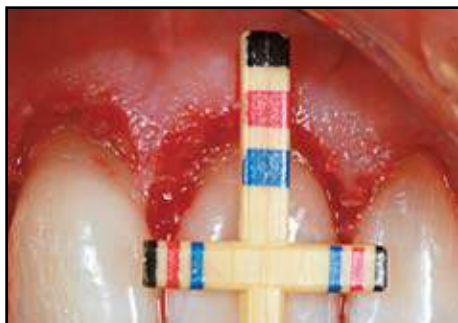
Figure 8A. The appropriate interdental papilla length was determined. 8B. The corresponding color-coded marking was used to determine the correct papilla length.

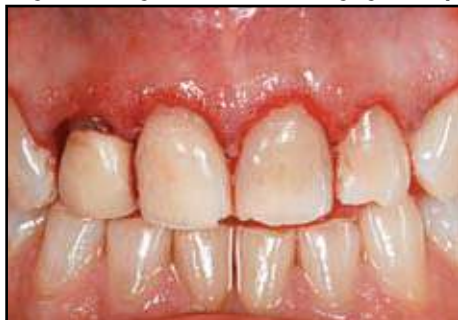



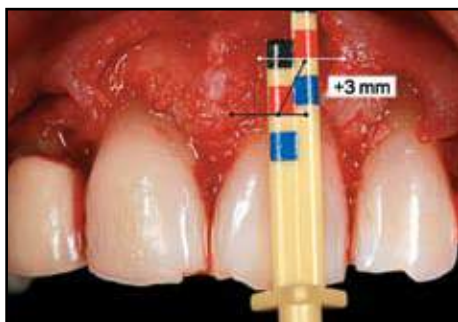**Figure 9.** Mid-facial and interdental sounding was performed to access the location of the osseous crest.



**Figure 10.** The T-Bar tip was used to verify the corrected tooth proportion and mid-facial tissue length following an internal beveled gingivectomy.



**Figure 11.** The gingivectomy was completed from the first premolar to the contralateral premolar.



**Figure 12.** The BLPG tip was used to ensure sufficient excision of mid-facial bone.

bar (Figure 7A). The corresponding outer edge of the inner yellow marking on the vertical bar was 9.5 mm, which yielded a width-to-length percentage of 79%. This proportion was within the ideal 73% to 86% statistical analysis of tooth proportion ratios both anatomically and clinically for the maxillary anterior dentition.<sup>12,13</sup>

Once the correct clinical length was established, the BLPG tip was positioned (Figure 7B). The markings on the shorter vertical arm of the BLPG corresponded exactly with the markings on the vertical arm of the PG. The colored markings on the longer vertical arm of the BLPG were over 3 mm greater than the corresponding markings on the shorter (clinical crown length) arm. It is to this length that bone would be recontoured in order to provide 3 mm of tooth structure for the placement of a restorative margin as well as space for the re-establishment of the biologic width.

The papilla tip was used to determine the appropriate location of the papilla relative to the corrected MF clinical crown length from the incisal edge position. The corrected MF position of the free gingival margin (FGM) and the corrected ID papilla position was then determined (Figure 8). This particular patient had a smaller-than-average tooth size that, when corrected, would be proportional; all corresponding measurements for correction of the MF and ID hard and soft tissues were based upon these smaller-than-average dimensions.

Sounding of the MF region and ID DGC took place prior to the gingivectomy, which was performed for each tooth to the desired color marking on the PG (Figures 9 and 10). The gingiva was then carefully flapped, keeping the palatal half of the interproximal papilla intact (Figure 11). The bone on the direct facial of the tooth was reduced to the appropriate length and recontoured in a parabolic fashion to the corresponding colored line on the longer arm of the BLPG (Figure 12). To prevent the attachment fibers from the ligament from proliferating coronally, it was important to thoroughly root plane the tooth surface to the crest of bone.<sup>14</sup> According to the literature, the junctional epithelium will subsequently migrate 3 mm apically on the planed root surface during healing, and it was anticipated that an additional 0.4 mm to 1 mm of crestal resorption would occur in order to establish a new supracrestal connective tissue fiber barrier.<sup>15</sup>

The ideal length of the papilla has been determined to be approximately 40% of the length of the tooth from the gingival zenith equivalent to 60% from the incisal edge position.<sup>6</sup> Studies show that as long as there is a vertical distance of 5 mm or less from the base of the contact to the crest of bone, the papilla will reform 99.3% of the time.<sup>2,3</sup> Recent research, however, has shown that papilla reformation is also dependent upon

the interradicular distance (width between the roots) of teeth,<sup>16,17</sup> and, once the roots are greater than 2.4 mm apart, papilla reformation tends to decrease if bone is absent. Therefore, the 3-mm to 5-mm rule gravitates to the 3-mm rule with increasing interradicular distance between tooth roots.

Recontouring of the crest of interproximal bone was, thus, performed judiciously to minimize the chances of losing the papilla. It was essential to blend the recontoured MF bone to the ID bone to achieve the desired hard and soft tissue papilla height correction. During aesthetic crown lengthening, the ID bone was recontoured around the buccal line angles in a mesiodistal direction and was festooned and thinned towards the palate interproximally in a buccolingual direction (Figure 13). Care was taken to ensure that the bone and the concomitant circulation supporting the palatal half of the papilla were kept intact. The papilla tip was used to guide the surgeon during the ID recontouring procedure to help determine the appropriate coronal-apical position of the ID papilla from a hard and soft tissue perspective (Figure 14).

How far to the palate the interproximal bone is recontoured will determine how much the papilla will be apically repositioned. When the buccal flap was subsequently replaced and sutured, the papillary portion of the flap was re-approximated more palatally and apically than the original position; thus moving the apical contact point of the proximal contact area apically. In addition, the buccal aspect of the ID papilla prone to sloughing was nourished by the palatal blood supply that had been left uncompromised during the recontouring and suturing procedure (Figure 15). Healing was rapid and uneventful, and the final restorations were placed in 6 to 8 weeks subsequent to the proper quantitative crown lengthening procedure. The T-Bar and papilla tips were used to confirm the stability of the MF and ID tissues, respectively, prior to restoration (Figures 16 through 19).

### Discussion

Surgical crown lengthening is routinely performed to re-establish the appropriate biologic width when either insufficient tooth structure exists or a violation of the dentogingival attachment has occurred. This technique has been previously described by many authors as a periodontal surgical technique requiring strict adherence to several basic tenants to establish the proper dimensions and relationship of the restorative margin, connective tissue attachment, junctional epithelium, and gingival sulcus. This article, in conjunction with "Part I," describes a new approach to crown lengthening in the aesthetic zone that is performed in a series of steps first initiated

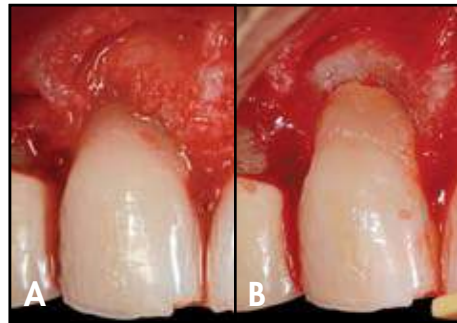


Figure 13A. Pre-osseous appearance. 13B. Post-osseous mid-facial and interdental recontouring.

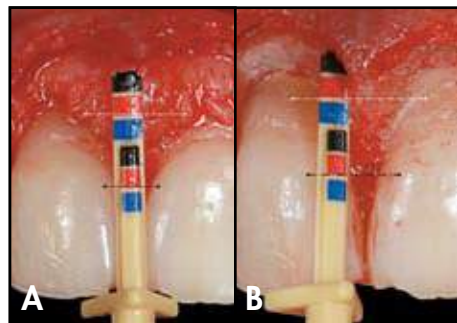


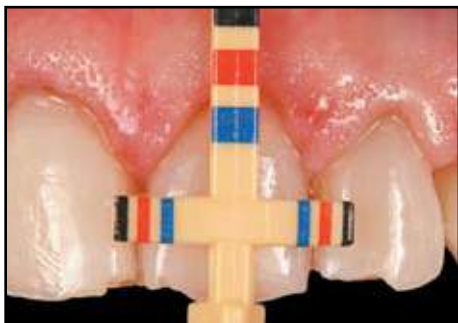
Figure 14A. The papilla tip of the crown lengthening gauge was used to determine the degree of papillary apical repositioning needed. 14B. The interradicular bone was reshaped both mesiodistally and buccolingually.

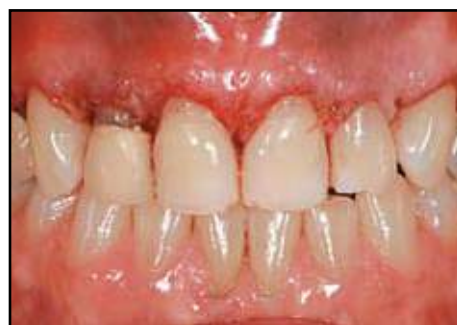

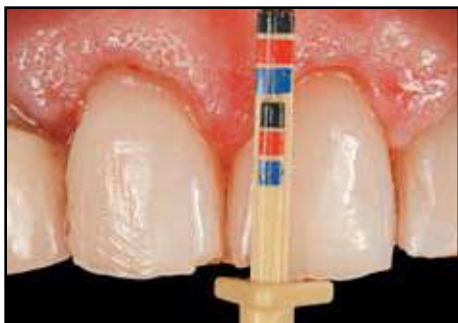Figure 15. The buccal flap was replaced and sutured, and the papillary portion of the flap was re-approximated in a more palatal and apical position.

by evaluating and determining the ideal tooth dimensions as they relate to the individual being treated within the parameters of appropriate tooth proportion ratios.<sup>18</sup>

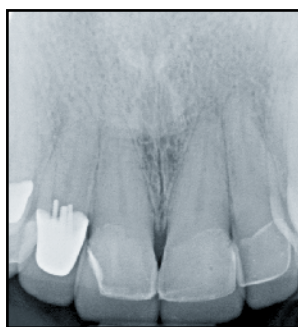Several authors have described surgical techniques developed to overcome the challenges that are present when attempting to perform aesthetic crown lengthening on multiple maxillary teeth. The use of a surgical template designed to be temporarily adapted to the maxillary anterior teeth has been discussed,<sup>19</sup> and a similar



**Figure 16.** The T-Bar tip of the tooth proportion gauge was used to confirm that the proper 80% width-to-length ratio was achieved.



**Figure 17.** The proper height of the interdental papilla was confirmed using the papilla tip.



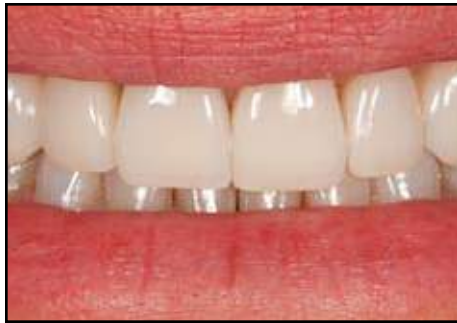**Figure 18.** Postoperative radiograph denotes the presence of sufficient interdental papillae and supporting bone.

concept of using temporary provisional restorations as a working surgical template has been mentioned in the literature.<sup>20</sup> These guides are used to define the amount of osseous removal during surgery, defining the osteotomy relative to template position. Guides primarily address MF tissue levels, but, less frequently, are designed to tackle the ID tissue location. In addition, the deficiencies of these techniques are in the use of the splinted multi-unit template that interferes with surgical site access. Templates

can vary in fit and position, be unstable, and dislodge during treatment, resulting in a loss of critical referencing measurements both mid-facially and interdental. The template technique requires additional cost and office visits toward its fabrication prior to performing the aesthetic crown lengthening procedure.

Several studies have confirmed that an ideal tooth proportion of approximately 80% (width/length) within maxillary anterior dentition exists.<sup>12,13</sup> Sterret, Spear, Kokich, Chiche, and others have previously reported the concept of utilizing individual tooth proportion in lieu of the "golden proportion" as an objective means when achieving ideal aesthetics.<sup>13,21-23</sup> This 80% tooth proportion value allows one to mathematically determine objective measurements when re-establishing the tooth width and length relative to the gingival architecture of the supporting periodontal tissues. The use of aesthetic gauges (ie, *Chu's Aesthetic Gauges*, Hu-Friedy, Inc, Chicago, IL) described herein, is an easy, efficient way to predictably determine proper tooth proportion based on a visual color-coded system. The established tooth proportion can be used to further determine the appropriate MF position and ID crest-of-bone position when aesthetic crown lengthening is required and performed.

These aesthetic gauges are predicated upon nuances in patient tooth size variance being the fundamental "building block" of a smile and reconstruction. This eliminates the need for multiple visits, thereby reducing cost to fabricate a surgical polymer-based template. The tooth proportion related to width and length are easily understood and recognized using the color-coded marking system that is found on all of the gauges. The only requisite to determining the proper tooth proportion is an intact incisal edge of the tooth. If the incisal edge is worn or altered, it needs to be restored prior to proceeding with measurement. When using the crown lengthening gauge, one can directly measure both the optimal location of the clinical crown length while simultaneously measuring the correct position of the osseous crest, ensuring that an adequate biologic width will be present once the surgical treatment is completed. This is the first technique that uses optimal tooth proportions to determine the correct position of the osseous topography, both mid-facially and interdental, supporting those teeth. Measurements are performed directly on the teeth with these disposable and removable aesthetic gauges so that they will not interfere with surgical instrumentation. The gauges can be used repeatedly to confirm and verify the amount of osseous tissue to be removed. Visual precision without estimation is vital for successful, predictable, cost-efficient treatment.



**Figure 19. Postoperative appearance demonstrates harmonious integration and aesthetic width-to-length proportions.**

Within the set of color-coded gauges, one can now accurately establish the MF crest-of-bone position by using the appropriate visual markers that were mathematically formulated, starting with tooth proportion; tooth length relative to tooth width. Similarly, the appropriate ID papilla height and crest of bone can be determined when using these color-coded instruments. Lastly, the appropriate position of the facial flap, as well as the ID papilla, can now be objectively determined, based on tooth proportion as the reference point to the aesthetic surgical procedure.

### Conclusion

Over the past decade, the growth of aesthetic dentistry has taken on a larger more prominent role in the services requested and provided. This has also influenced the type of procedures and techniques that have evolved over time. Techniques that were previously performed to primarily restore health have been adapted to provide primary benefits to an aesthetic restorative outcome. One such technique that fits this evolutionary model is periodontal crown lengthening surgery. This surgical technique is more appropriately described as *aesthetic crown lengthening surgery*, where the primary objective is to enhance the gingival contour, form, and position of the attachment apparatus relative to individual tooth proportion within the oral region known as the *aesthetic zone*.

### Acknowledgements

The authors mention their gratitude to Dr. Brad McAllister and Dr. Vincent Locona as members of a product development focus group. Dr. Chu is the creator of *Chu's Aesthetic Gauges* and continues to serve as a consultant for *Hu-Friedy, Inc.*

### References

- Gargiulo AW, Wentz FM, Orban B. Dimensions and relations of the dento-gingival junction in humans. *J Periodontol* 1961;32:261-267.
- Kois JC. Altering gingival levels: The restorative connection. Part I: Biologic variables. *J Esthet Dent* 1994;6(1):3-9.
- Tarnow DT, Magner AV, Fletcher P. The effect of the distance from the contact point to the crest of bone on the presence or absence of the interproximal dental papilla. *J Periodontol* 1992;63(12):995-996.
- Nevins M, Skurrow HM. The intracrevicular restorative margin, the biological width, and the maintenance of the gingival margin. *Int J Periodont Rest Dent* 1984;4(3):30-49.
- Rosenberg ES, Cho SC, Garber DA. Crown lengthening revisited. *Comp Contin Educ Dent* 1999;20(6):527-542.
- Chu SJ, Tarnow DP, Tan JHP, Stappert CFJ. Papilla height to crown length proportions in the maxillary anterior dentition. Manuscript submitted for publication. *Int J Periodont Rest Dent* 2008.
- Schroeder HE. Quantitative parameters of early human gingival inflammation. *Arch Oral Biol* 1970;15(5):383-400.
- Chu SJ. Range and mean distribution frequency of individual tooth width of the maxillary anterior dentition. *Pract Proced Aesthet Dent* 2007;19(4):209-215.
- Chu SJ. A biometric approach to predictable treatment of clinical crown discrepancies. *Pract Proced Aesthet Dent* 2007;19(7):401-409.
- LaVacca MI, Tarnow DP, Cisneros GJ. Interdental papilla length and the perception of aesthetics. *Pract Proced Aesthet Dent* 2005;17(6):405-412.
- Herrero F, Scott JB, Maropis PS, Yukna RA. Clinical comparison of desired versus actual amount of surgical crown lengthening. *J Periodontol* 1995;66(7):568-571.
- Magne P, Gallucci GO, Belser UC. Anatomic crown width/length ratios of unworn and worn maxillary teeth in white subjects. *J Prosthet Dent* 2003;89(5):453-461.
- Sterret JD, Oliver T, Robinson F, et al. Width/length ratios of normal clinical crowns of the maxillary anterior dentition in man. *J Clin Periodontol* 1999;26(3):153-157.
- Oakley E, Rhyu IC, Karatzas S, et al. Formation of the biologic width following crown lengthening in nonhuman primates. *Int J Periodont Rest Dent* 1999;19(6):529-541.
- Carnevale G, Sterrantino S, Di Febo G. Soft and hard tissue wound healing following tooth preparation to the alveolar crest. *Int J Periodont Rest Dent* 1983;3(6):37-53.
- Cho HS, Jang HS, Kim DK, et al. The effect of interproximal distance between roots on the existence of interdental papillae according to the distance from the contact point to the alveolar crest. *J Periodontol* 2006;77(10):1651-1657.
- Martegani P, Silvestri M, Mascarello F, et al. Morphometric study of the interproximal unit in the esthetic region to correlate anatomic variables affecting the aspect of soft tissue embrasure space. *J Periodontol* 2007;78(12):2260-2265.
- Chu SJ, Hochman MN. A biometric approach to aesthetic crown lengthening: Part 1—Midfacial considerations. *Pract Proced Aesthet Dent* 2008;20(1):17-24.
- Walker M, Hansen P. Template for surgical crown lengthening: Fabrication technique. *J Prosthodont* 1998;7(4):265-267.
- Lee EA. Aesthetic crown lengthening: Classification, biologic rationale, and treatment planning considerations. *Pract Proced Aesthet Dent* 2004;16(10):769-778.
- Kokich VG, Spear FM. Guidelines for managing the orthodontic-restorative patient. *Semin Orthod* 1997;3(1):3-20.
- Kokich VG. Esthetics: The orthodontic-periodontic restorative connection. *Semin Orthod* 1996;2(1):21-30.
- Chiche GJ, Pinault A. Artistic and scientific principles applied to esthetic dentistry. In: Chiche GJ, Pinault A, eds. *Esthetics of Anterior Fixed Prosthodontics*. Chicago, IL: Quintessence Publishing; 1990:13-32.